



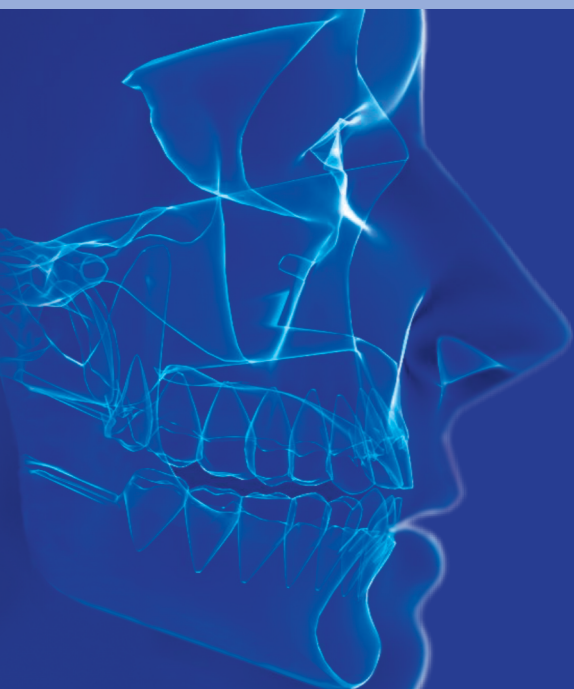ams

Annals of Maxillofacial Surgery

Official Publication of The Indian Academy of Maxillofacial Surgery

www.amsjournal.com

Estd : 1996



Effects of Corticobasal Implant Protrusion inside the Nasal and Maxillary Sinus

Fadia Awadalkreem, Abdelnasir Gafar Ahmad¹, Stefan Ihde², Motaz Osman³

Department of Oral Rehabilitation, Prosthodontic Division, Faculty of Dentistry, University of Khartoum, ¹Department of Oral and Maxillofacial Surgery, Faculty of Dentistry, International University of Africa, ³Department of Implantology, Khartoum Teaching Dental Hospital, Federal Ministry of Health, Khartoum, Sudan, ²Department of Evidence and Research, International Implant Foundation, Munich, Germany

Abstract

Background: Implant protrusion into the nasal and maxillary sinuses presents a challenge in cases of severely resorbed maxillae. **Aim:** The aim of this study was to evaluate the clinical and radiographic effects of BECES[®] implant penetration depth into the nasal and maxillary sinuses. **Setting and Design:** This was an observational study conducted in a tertiary institution. **Materials and Methods:** Forty-nine BECES[®] implants were inserted into the maxilla of patients who presented with severely resorbed ridges but no history of sinusitis. Forty-five implants protruded into the sinus cavities. Patients were examined clinically and radiographically at 1 week and 3, 6, 12, and 18 months after insertion. Maxillary sinus health, survival and success rates, and peri-implant health were assessed using the plaque index (PI), calculus index, modified gingival index (MGI), and probing pocket depth (PPD). **Statistical Analysis:** Wilcoxon signed-rank test and Mann–Whitney test were used in this study. **Results:** Four (8.16%) of the 45 implants that penetrated the cavities reached the sinus floor without disrupting the membrane; the penetration depth was ≥ 4 mm in 20 implants (44.44%) and < 4 mm in 25 (55.56%). No patient showed clinical or radiographic signs of sinusitis during the observation period. There were significant differences in the PI, MGI, and PPD values between baseline and the 18-month follow-up with no association with the penetration depth. All implants showed radiographically direct bone-to-implant contact. Where the implant tip barely reached the sinus floor, the membrane healed uneventfully while when deeply penetrating the sinus, the membrane healed around the implant but did not cover the tip. All prostheses and implants survived during the observation period. **Conclusion:** Penetration depth of polished implants with cortical engagement into the maxillary sinus or the floor of the nose does not negatively affect implant survival, the success rate of the treatment, nor peri-implant soft-tissue health. It also does not provoke the development of sinusitis.

Keywords: BECES[®] implant, cortical engagement of implants, corticobasal implant, maxillary sinus, nasal sinus

INTRODUCTION

Many methods have been described for the management of complete and partial edentulism. Recently, implant treatment has become the gold standard for replacing missing teeth if adequate bone is present.^[1] Cases of severe alveolar ridge resorption remain a challenge in dental implantology.^[1-3] The posterior maxilla often presents with limited bone height and poor bone quality, which jeopardizes the primary stability of the implant. A further problem is the complication of maxillary sinus “pneumatization.”^[1,3-6]

Conventional maxillofacial therapy has devised methods to increase the bone quantity in cases of severe bone loss, such

as sinus lifting and sinus augmentation procedures with bone grafts harvested from the hip, tibia, ribs, or chin followed by insertion of the implant.^[1,3] This procedure was first documented by Boyne and James in 1980^[7] and subsequently

Address for correspondence: Dr. Fadia Awadalkreem,
Department of Oral Rehabilitation, Prosthodontic Division, P.O. Box 102,
Faculty of Dentistry, University of Khartoum, Army Rd., Khartoum, Sudan.
E-mail: fadiadent@hotmail.com

Submitted: 11-02-2020

Revised: 22-02-2020

Accepted: 29-02-2020

Published: 08-06-2020

This is an open access journal, and articles are distributed under the terms of the Creative Commons Attribution-NonCommercial-ShareAlike 4.0 License, which allows others to remix, tweak, and build upon the work non-commercially, as long as appropriate credit is given and the new creations are licensed under the identical terms.

For reprints contact: WKHLRPMedknow_reprints@wolterskluwer.com

How to cite this article: Awadalkreem F, Ahmad AG, Ihde S, Osman M. Effects of corticobasal implant protrusion inside the nasal and maxillary sinus. *Ann Maxillofac Surg* 2020;10:114-21.

Access this article online

Quick Response Code:



Website:
www.amsjournal.com

DOI:
10.4103/ams.ams_42_20

by Tatum.^[8] Summers^[9] introduced the sinus floor elevation technique using an osteotome with a flapless crestal approach, possibly accompanied by simultaneous placement of an implant.

Although a bone augmentation procedure can increase the bone height and width, it has some disadvantages, including the need for two independent invasive surgical procedures, which not only prolongs the treatment significantly but also results in additional costs and risks as well as patient discomfort.^[10,11]

Numerous postoperative complications of sinus lifting procedures have been reported, including wound dehiscence, acute/chronic sinusitis, mucocele formation, swelling, discharge of graft material into the sinus, and graft infection resulting in complete loss of the graft and continuing morbidity at the donor site.^[10-15]

Furthermore, sinus lifting procedures have been associated in many studies with the risk of perforation of the sinus membrane. The literature reports a 44% incidence of sinus membrane perforation during implant osteotomies and/or implant placement.^[15] Consequently, implants protrude into the nasal or maxillary sinuses. Reports on the effects of this protrusion on the health of the nasal and maxillary sinuses are mixed. Several groups have found no adverse effects^[1,3,4,16-25] while others have reported mild adverse effects.^[3,24]

An electronic and manual literature search by Ragucci *et al.*^[3] reported after penetration of implants through the floor of the maxillary sinus a clinical complication rate of 14.8%, among which epistaxis being the most common side effect. They also found a radiographic complication rate of 3.4%, the most common being thickening of the Schneiderian membrane, with no significant difference according to the level of implant penetration. However, they documented a survival rate of about 95.6%, with no significant effect of level of implant penetration. They classified the implant penetration depths into two groups (>4 mm and ≤4 mm), and the results for both groups were the same.

In the past few years, several authors have recommended the use of Corticobasal[®] implants to achieve bicortical anchorage (e.g., crest of the ridge and maxillary sinus floor) and to ensure implant stability in patients with severe ridge resorption or compromised bone support.^[26-36] Consequently, implants may have exposed to the nasal and maxillary sinuses [Figure 1] with possible challenging effects. Although many studies have reported that Corticobasal[®] (BECES[®]) implants have very favorable outcomes with limited and manageable complications,^[27-29,34-36] there is still some doubt concerning the effect of their penetration into the nasal and maxillary sinuses. In 2018, Lazarov^[37] published a prospective cohort study in which patients treated with Strategic Implant[®] technology who underwent placement of 375 BCS[®] implants in 105 maxillary sinuses were followed for 3–4.5 years. The maxillary sinuses were assessed preoperatively on panoramic views and clinical examination. Patients with symptoms of

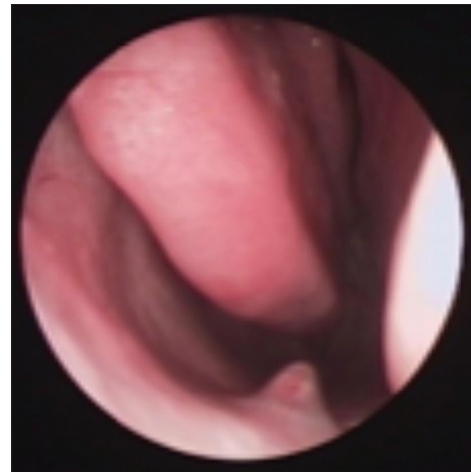

Figure 1: A clinical photograph showing an implant that is potentially protruding into the nasal cavity using sinuscopy

acute sinusitis were not treated until their symptoms had disappeared. Postoperative control panoramic views were taken and clinical examinations were performed in all patients at 3 years and 4.5 years. Only one sinus showed radiographic and clinical symptoms of a sinusitis. Lazarov concluded that polished implants placed in such a way to intentionally or unintentionally penetrate the maxillary sinus do not cause any sinus reaction, and they can remain stable for many years. Furthermore, all symptoms of sinusitis were transient and resolved completely after various treatments even though the implants were left in place. Little information is available concerning the peri-implant health of the mucosa around penetration areas in the maxillary and nasal sinuses.

The aim of the present study was to evaluate the effect of protrusion of a BECES[®] implant inside the nasal and maxillary sinuses and to investigate the effect of penetration depth on peri-implant health and the implant survival rate.

MATERIALS AND METHODS

Characteristics of the study sample

The study was approved by the ethics committees of the hospital and the Ministry of Health, Khartoum, Sudan. All patients who underwent Corticobasal[®] implant treatment between 2015 and 2017 and presented with severe alveolar ridge resorption with possible protrusion of an implant inside the nasal or sinus cavity were asked to participate in the study. All patients provided informed consent for participation in the study and publication of the results after receiving a detailed explanation of the objectives of the study, the protocol, and the possible complications.

The study inclusion criteria were age 18–80 years and complete or partial edentulism. All patients had severe ridge resorption and requested implant treatment. The patients were questioned about their history and symptoms of maxillary sinusitis,^[38] including nasal bleeding, congestion, or obstruction, nasal secretion, and pain or tenderness in the infraorbital region.

Patients with a history of sinusitis or bisphosphonate therapy were excluded.

Surgical and prosthetic procedures

Preoperative cone-beam computed tomography (CBCT) scans (Planmeca ProMax; Planmeca, Budapest, Hungary) were obtained for all patients. The scans were obtained using a standardized technique with the same scanner. All images were analyzed under standardized conditions. The implants were placed under local infiltration anesthesia with 2% lidocaine and epinephrine 1:100,000 after application of Betadine 5% at the implant sites. The implant osteotomy was performed using a drill with copious irrigation, followed by cortical penetration, administration of 2 ml of Betadine 5%, and placement of the implant. All implants (BECES® Brand, Manufacturer Simpladent GmbH, CH-8737, Gommiswald, Switzerland) were inserted using a standard one-stage surgical procedure. The length and width of the implant were selected according to the amount of available bone. High primary stability was achieved and tested using the reverse-torque technique at 35 Ncm. Amoxicillin and clavulanate potassium (Megamox, 1 mg; Hikma Pharmaceuticals, Amman, Jordan), diclofenac potassium (Rapidus, 50 mg; Tabuk Pharmaceutical Manufacturing Co., Tabuk, Kingdom of Saudi Arabia), and xylometazoline (Otrivine, adult nasal drops; GlaxoSmithKline, Brentford, UK) were prescribed for all patients. The penetration depth of the implant was measured on CBCT scans obtained postoperatively using the machine's software.

Impression copings were secured to the head of the implant, and an impression was taken using monophasic vinyl polysiloxane (Ivoclar Vivadent AG, Schaan, Liechtenstein). The metal framework was constructed on the following day, and a heavy body silicone jaw relation was taken. This metal framework was used to provide implant splinting, to reduce load per unit area, and to ensure better force distribution that minimizes the possible causes of implant overloading. Either acrylic or composite veneer material was applied to the framework depending on the extent of loss of soft and hard tissues. One day later (within 72 h), the final prosthesis was inserted and cemented using Fuji cement (Fuji I Luting Cement, GC Corporation, Tokyo, Japan). Patients were scheduled for follow-up clinical and radiographic examinations at 1 week and 3, 6, 12, and 18 months.

Follow-up evaluation

Sinuses

Any signs and symptoms of sinusitis such as mucopurulent drainage, nasal obstruction, facial pain/pressure/fullness, headaches, and an impaired sense of smell were noted.^[38]

Implant success and survival rates

In line with the literature, implant survival was defined as the presence of the implant in the mouth at the time of examination.^[39] The implant success rate was assessed using the modified James–Misch implant quality of health scale^[39] (I, success [optimum health]; II,

survival [satisfactory health]; III, survival [compromised health]; and IV, failure [clinical or absolute failure]), the Albrektsson^[40] criteria for implant success, which includes a bone loss of <1.5 mm in the 1st year and <0.2 mm yearly thereafter, and the presence of suppuration and peri-implant infection, continuous pain, mobility, or persistent peri-implant radiolucency.^[40] The sample was categorized into two groups, i.e., those with an implant penetration depth ≥ 4 mm and those with a penetration depth <4 mm measured on CBCT.^[3]

Clinical examination

Peri-implant soft tissue

The plaque index (PI) is a three-point scale devised by Mombelli *et al.*^[41] (0, plaque detected; 1, plaque detected by running a probe across the implant; 2, plaque visible to the naked eye; and 3, abundance of plaque). The modified gingival index (MGI) was determined according to the modified Loe and Silness index^[42] (0, absence of inflammation [normal peri-implant mucosa]; 1, mild inflammation [slight change in color] and slight edema; 2, moderate inflammation [redness, edema, and glazing]; and 3, severe inflammation [marked redness and edema] and ulceration). The calculus index (CI) was reported based on its presence or absence of calculus around the implants both labially and lingually (1, presence and 0, absence). The CI was reported as a yes/no variable. The probing pocket depth (PPD) was measured in millimeters using a short-shank probe with gentle pressure from the mucosal margin to the bottom of the pocket in both a labial/buccal and palatal direction.^[42] If complete peri-implant soft-tissue healing around the implants had been achieved, the pocket depth was reported as 0 mm; introduction of the probe was prohibited given that “consensus on probing around basal implants”^[43] does not recommend probing as a routine step. However, these data should be assessed and reported for comparison with other implant studies. Patients were asked about their level of satisfaction, any complaints, and whether or not they would choose the same treatment modality again.

The implant penetration depth and the mean PI, MGI, and PPD scores were recorded at five follow-up visits. The mean was then categorized as: 0 = 0, 0.2–0.4 = 1, 0.6–1.0 = 2, and 2 = 3 for calculation of the associations between penetration depth and the index scores and PPD using contingency coefficient and Chi-square tests.

Prostheses

The prostheses were inspected for decementation, lip support, extent of visible smile, mobility, unnatural wear of the opposing dentition, and fracture of the veneer material.

Radiographic evaluation

Radiographic assessment was performed using CBCT to detect implant loss and/or fracture, to evaluate bone-to-implant contact, and to detect any changes in the nasal and maxillary sinuses at 1 week and 6, 12, and 18 months. The intrarater reliability was determined using repeated measurements at varying time intervals spanning several days and was 0.95, 1, 1, and 0.90 for the PI, CI, MGI, and PPD, respectively.

Statistical analysis

The Wilcoxon signed-rank test was used to compare the PI, modified MGI, and PPD between baseline and the 18-month follow-up visit. All data recording and statistical analyses were performed using the Statistical Package for the Social Sciences (SPSS) software (SPSS version 22; IBM Corp., New York, NY, USA). $P < 0.05$ was considered statistically significant. The 95% confidence interval was also calculated.

RESULTS

Sample distribution

Forty-nine implants were found to have penetrated into the nasal and maxillary sinus cavities. The mean patient age was 63.6 ± 14.22 years. The immediate (baseline) postoperative radiographs revealed that 4 (8.16%) of the 45 implants that had penetrated the nasal and sinus cavities had reached the sinus floor without disrupting the membrane; the penetration depth was ≥ 4 mm for 20 implants (44.44%) and < 4 mm in 25 (55.56%).^[3]

Nasal and maxillary sinuses

Clinical findings

None of the patients showed any signs or symptoms of rhinitis or sinusitis during follow-up. All patients maintained good oral hygiene without pain or implant-related exudates.

Radiographic findings

Comparison of the radiographs obtained at 6, 12, and 18 months with those obtained at baseline did not reveal any inflammatory reactions at or around the implants, signs of osteolytic reactions, polyps or granulation around the implants inside the sinuses, lost implants, or implant fractures. All implants showed newly regenerated bone surrounding the threads, indicating an increase in the bone-to-implant contact despite the different penetration depths [Figures 2 and 3]. For those implants that merely penetrated or disrupted the sinus membrane, it was found that the membrane had healed and tended to cover the implant tips [Figure 2a and b]. When the implant penetrated the maxillary sinus deeply, there was still an increase in bone contact around the implant; in these cases, the membrane healed around the tip of the implant but did not cover it [Figure 3a and b].

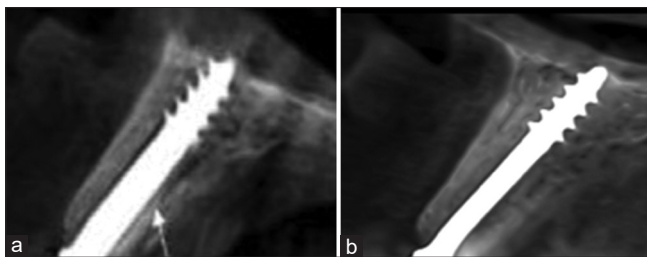


Figure 2: Cone-beam computed tomography scans showing an implant that just barely made contact with the Schneiderian membrane. (a) Immediately after implant insertion. (b) At the 18-month follow-up visit. There are no inflammatory reactions at or around the implant, no signs of an osteolytic reaction, no polyps, and no granulation around the implant inside the sinuses. The implant shows an increase in bone-implant contact

Implant health and survival rate

According to the implant health assessment scale,^[39] all patients presented with optimum health at the 18-month follow-up, with no pain or tenderness on function, no (zero) mobility, not more than 2 mm of radiographic bone loss from baseline, and no history of exudates. Therefore, the implant survival and success rates were both 100%.^[39]

Peri-implant soft tissue

There was a statistically significant difference in the PI score between baseline and the 18-month follow-up [$P = 0.038$, Wilcoxon signed-rank test; Table 1]. Despite the reported increase in the PI readings in some patients, the score ranged between 0 and 2 [Table 1]. The CI did not change over time in any case [mean 0.00 ± 0.00 ; Table 1]. There was also a significant decrease in the MGI score ($P = 0.025$, Wilcoxon signed-rank test). The mean was 0.22 (range, 0–1). There was a significant decrease in the PPD ($P = 0.003$, Wilcoxon signed-rank test) with a range of readings from 0 mm to 3 mm. Clinical examination revealed that the soft tissue healed very rapidly even in sites where implants were inserted into fresh extraction sockets and a complete soft-tissue collar present around the vertical shaft of the implants.

Association between implant penetration depth and plaque index, modified gingival index, and probing pocket depth values

There was no significant difference in the PI, MGI, or PPD value according to implant penetration depth [$P = 0.066$, $P = 0.283$, and $P = 0.550$, respectively, Mann-Whitney test; Table 2]. Moreover, there was no association between implant penetration depth (≥ 4 mm or < 4 mm) and the PI, MGI, and PPD values [$P = 0.116$, $P = 0.262$, and $P = 0.480$, respectively; Tables 3–5]. There was an apparent increase in the peri-implant bone level exhibited around the vertical shafts and horizontal plates in all implants [Figures 2 and 3].

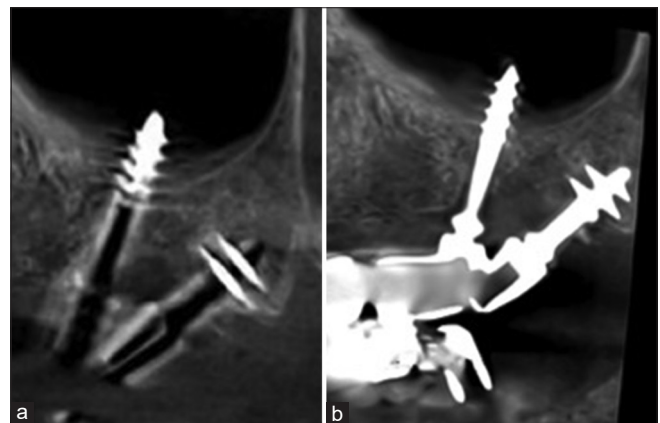


Figure 3: A cone-beam computed tomography scan showing an implant that penetrated the Schneiderian membrane and beyond, deep into the maxillary sinus. (a) Immediately after implant insertion. (b) At the 18-month follow-up visit. There are no inflammatory reactions at or around the implant, no signs of an osteolytic reaction, no polyps, and no granulation around the implant inside the sinuses. The implant shows an increase in bone-implant contact

Patient satisfaction

All patients were satisfied with their treatment, reported an improvement in their quality of life, and said they would choose the same treatment again.

DISCUSSION

Resorption of the residual alveolar ridge following a tooth extraction, as well as pneumatization of the maxillary

Table 1: Comparison of the plaque index, modified gingival index, and probing pocket depth values between baseline and the 18-month follow-up visit

Peri-implant soft tissue	Mean±SD		P
	Baseline	18 months	
PI	0.000±0.000	0.18±0.535	0.038
CI	0.000±0.000	0.000±0.000	-
MGI	0.110±0.318	0.090±0.288	0.025
PPD	0.580±0.818	0.200±0.505	0.003

Nonparametric Wilcoxon signed-rank test. SD: Standard deviation, PI: Plaque index, CI: Calculus index, MGI: Modified gingival index, PPD: Probing pocket depth

Table 2: Comparison of the plaque index, modified gingival index, and probing pocket depth values between baseline and the 18-month follow-up visit according to implant penetration depth

Peri-implant soft tissue	Penetration depth (mean±SD)		P
	<4 mm	≥4 mm	
PI	0.040±0.115	0.130±0.208	0.066
CI	0.000±0.000	0.000±0.000	-
MGI	0.040±0.100	0.170±0.117	0.283
PPD	0.256±0.460	0.240±0.249	0.550

The Mann-Whitney test was used. SD: Standard deviation, PI: Plaque index, CI: Calculus index, MGI: Modified gingival index, PPD: Probing pocket depth

Table 3: Association between implant penetration depth and plaque index value

PI	Penetration depth		Total	P
	<4 mm	≥4 mm		
0				0.116
Count	22	13	35	
Percentage of total	48.9	28.9	77.8	
0.2-0.4				
Count	3	5	8	
Percentage of total	6.7	11.1	17.8	
0.6-1.0				
Count	0	2	2	
Percentage of total	0.0	4.4	4.4	
Total				
Count	25	20	45	
Percentage of total	55.6	44.4	100	

PI: Plaque index

sinus, can compromise the placement of a dental implant in the maxillary posterior region. Several researchers^[26,32,33] have recommended anchorage of bicortical crestal bone and the sinus floor implant to improve implant stability in patients with limited bone quality. Consequently, implants may protrude into the maxillary or nasal sinuses, resulting in perforation of the maxillary sinus membrane.

Although some studies have reported an incidence of sinusitis associated with implant penetration inside the maxillary sinus, other studies have reported no change in the maxillary sinus, and there are a number of reports of epistaxis as common clinical complications and thickening of the Schneiderian membrane as the main radiographic complication. Therefore, there was a need for a clinical study with a longer observation period to investigate these controversial results.

According to the literature,^[1,44] sinusitis of dental origin accounts for about 10%–12% of all cases of maxillary sinusitis and is associated with many etiological factors, including dental infections, such as periapical granuloma, periapical abscess, periodontal infection, inflammatory cyst, oroantral fistula, a foreign body introduced inside the sinus (such as filling material, root fragment, broken instrument, and large odontogenic cyst),^[45-47] and a migrated dental implant.^[5,48-51] In the present study, although some of the implants investigated showed penetration of >4 mm, there was no clinical or radiographic evidence of adverse effects in the nasal or maxillary sinuses, such as nasal decongestion, sinusitis, polyp formation, or mucocele. This finding is in accordance with previous reports^[1,4,16-23] that revealed no association between implant protrusion into the maxillary sinus per se with the incidence of maxillary sinusitis. This observation could be attributed to the smooth surface of the implant and the small insertion tip that limits the interruption of the blood supply, resulting in the rapid healing of peri-implant soft tissue.^[27,28,32] Petruson^[49] reported normal mucosal conditions with no signs of increased secretion or infection around implants in which the tip penetrated the nasal or maxillary sinus even though the surface of the implants used in their study was rough.^[49]

Variable implant penetration levels were noted in this study; in the case of minor penetration, the membrane healed and covered the tip of the implant. This is confirmed the observations of Zhong *et al.*,^[4] who reported that a surgically disrupted membrane around the apical portion of an implant healed and covered the tips of the implants if the protruding depth was <2 mm. Jung *et al.*^[17,18] found that the sinus mucosa covered implants penetrating the sinus floor by <2 mm in mongrel dogs. Computed tomography scans showed that implant protrusion of >4 mm in the maxillary sinus caused thickening of the sinus mucosa around the implants; however, these sinuses remained asymptomatic. In contrast, Nooh^[24] reported that perforation of the membrane with dental implants may be associated with minor manageable complications, such as epistaxis and sinusitis.^[24]

The high implant survival rate in this study was in accordance with that in the study by Ragucci *et al.*,^[3] who reported survival

Table 4: Association between implant penetration depth and modified gingival index

MGI	Depth of penetration		Total	P
	<4 mm	≥4 mm		
0				0.262
Count	21	14	35	
Percentage of total	46.7	31.1	77.8	
0.2-0.4				
Count	4	6	10	
Percentage of total	8.9	13.3	22.2	
Total				
Count	25	20	45	
Percentage of total	55.6	44.4	100	

MGI: Modified gingival index

Table 5: Association between implant penetration depth and probing pocket depth

PPD	Penetration depth		Total	P
	<4 mm	≥4 mm		
0				0.480
Count	15	9	24	
Percentage of total	33.3	20.0	53.3	
0.2-0.4				
Count	6	6	12	
Percentage of total	13.3	13.3	26.7	
0.6-1.0				
Count	3	5	8	
Percentage of total	6.7	11.1	17.8	
Total				
Count	25	20	45	
Percentage of total	55.6	44.4	100	

PPD: Probing pocket depth

rates of 99.5% and 98.5% with implants that have a penetration depth of ≤4 mm and >4 mm, respectively, with no significant difference between the two depths. Nooh^[24] mentioned an overall survival rate of about 98.4% after 1 year of follow-up. Seven patients showed mild epistaxis during the immediate postoperative period, and there was one case of sinusitis.

The mean PI reported in this study was in line with that reported by Mombelli *et al.*,^[52] who rated the amount of plaque accumulation around the surface of the submucosal aspect of the implant-abutment on a scale from 0 to 3. The use of acrylic resin as a veneering material to compensate for the severe loss of soft and hard tissues may have caused the increased plaque accumulation on the restorations. This finding confirms the observations of other investigators^[53-55] who reported that the micropores and structural inconsistencies of the acrylic surface supported adhesion of dental plaque and microorganisms.

The excellent results for the MGI are credited to the smooth polished surface that allows rapid attachment of soft tissue around the implants. The polished vertical implant slot prevents adherence of plaque and apical transmission of the

bacterial load inside the basal aspect of the implant, far away from the site of bacterial infection (the oral cavity). Our observations confirmed the results of Ihde *et al.*,^[31,33] Lazarov,^[27] Ahmad *et al.*,^[28] and Singh *et al.*,^[29] who recommended this implant design for use at compromised implant sites, such as the maxillary sinus, the floor of the nose (where retrograde peri-implantitis could occur), or extraction sockets. These results are similar to the experimental and clinical results in maxillofacial traumatology and orthognathic surgery, in which penetration of smooth bone screws into the sinus and the nasal aspect of the floor of the nose did not result in any complications, infection, or bone loss.^[56,57]

The increased bone-to-implant contact found in this study is consistent with the finding of Khairnar and Gaur,^[20] who reported increased bone formation and excellent primary stability after indirect elevation of the nasal membrane with smooth polished implant. Zhong *et al.*^[4] found high removal torques and intimate bone-to-implant contact in bicortical implants in rabbits. Furthermore, Kim *et al.* reported a 100% implant survival rate with a significant increase in bone around the implants when the initial residual bone is <5 mm in height.

All patients in this study presented with severe ridge resorption that precluded rehabilitation with conventional implant-supported prostheses unless preceded by bone-grafting procedures. However, any removable prostheses made for such patients may be associated with compromised retention and stability due to the poor status of the denture-bearing area. Rehabilitation of these patients with fixed basal implant-supported prostheses greatly improved their satisfaction. This result is in line with other studies conducted with conventional dental implants.^[58-61]

CONCLUSION

Based on the clinical and radiographic evaluation of the patients in this study (within the limitations of a small sample size and short follow-up period), we can conclude that protrusion of a BECES® implant into the nasal or maxillary sinuses does not compromise the success or survival rate of the implant nor the health of the sinuses. Both the implants and the peri-implant soft tissues in this study were deemed to be in excellent health. Further research should be performed using larger samples and more extended follow-up periods.

Financial support and sponsorship

Nil.

Conflicts of interest

There are no conflicts of interest.

REFERENCES

1. Abi Najm S, Malis D, El Hage M, Rahban S, Carrel JP, Bernard JP. Potential adverse events of endosseous dental implants penetrating the maxillary sinus: Long-term clinical evaluation. *Laryngoscope* 2013;123:2958-61.
2. Henry PJ. Tooth loss and implant replacement. *Aust Dent J* 2000;45:150-72.

3. Ragucci GM, Elnayef B, Suárez-López Del Amo F, Wang HL, Hernández-Alfaro F, Gargallo-Albiol J. Influence of exposing dental implants into the sinus cavity on survival and complications rate: A systematic review. *Int J Implant Dent* 2019;5:6.
4. Zhong W, Chen B, Liang X, Ma G. Experimental study on penetration of dental implants into the maxillary sinus in different depths. *J Appl Oral Sci* 2013;21:560-6.
5. Galindo-Moreno P, Padiál-Molina M, Avila G, Rios HF, Hernández-Cortés P, Wang HL. Complications associated with implant migration into the maxillary sinus cavity. *Clin Oral Implants Res* 2012;23:1152-60.
6. Nolan PJ, Freeman K, Kraut RA. Correlation between Schneiderian membrane perforation and sinus lift graft outcome: A retrospective evaluation of 359 augmented sinus. *J Oral Maxillofac Surg* 2014;72:47-52.
7. Boyne PJ, James RA. Grafting of the maxillary sinus floor with autogenous marrow and bone. *J Oral Surg* 1980;38:613-6.
8. Tatum H Jr. Maxillary and sinus implant reconstructions. *Dent Clin North Am* 1986;30:207-29.
9. Summers RB. A new concept in maxillary implant surgery: The osteotome technique. *Compendium* 1994;15:152, 154-6.
10. Barone A, Santini S, Sbordone L, Crespi R, Covani U. A clinical study of the outcomes and complications associated with maxillary sinus augmentation. *Int J Oral Maxillofac Implants* 2006;21:81-5.
11. Shlomi B, Horowitz I, Kahn A, Dobriyan A, Chaushu G. The effect of sinus membrane perforation and repair with Lambone on the outcome of maxillary sinus floor augmentation: A radiographic assessment. *Int J Oral Maxillofac Implants* 2004;19:559-62.
12. Misch K, Wang HL. Implant surgery complications: Etiology and treatment. *Implant Dent* 2008;17:159-68.
13. Proussaefs P, Lozada J, Kim J, Rohrer MD. Repair of the perforated sinus membrane with a resorbable collagen membrane: A human study. *Int J Oral Maxillofac Implants* 2004;19:413-20.
14. Anavi Y, Allon DM, Avishai G, Calderon S. Complications of maxillary sinus augmentations in a selective series of patients. *Oral Surg Oral Med Oral Pathol Oral Radiol Endod* 2008;106:34-8.
15. Schwartz-Arad D, Herzberg R, Dolev E. The prevalence of surgical complications of the sinus graft procedure and their impact on implant survival. *J Periodontol* 2004;75:511-6.
16. Jeong SM, Choi BH, Li J, Xuan F. A retrospective study of the effects of sinus membrane elevation on bone formation around implants placed in the maxillary sinus cavity. *Oral Surg Oral Med Oral Pathol Oral Radiol Endod* 2009;107:364-8.
17. Jung JH, Choi BH, Zhu SJ, Lee SH, Huh JY, You TM, *et al.* The effects of exposing dental implants to the maxillary sinus cavity on sinus complications. *Oral Surg Oral Med Oral Pathol Oral Radiol Endod* 2006;102:602-5.
18. Jung JH, Choi BH, Jeong SM, Li J, Lee SH, Lee HJ. A retrospective study of the effects on sinus complications of exposing dental implants to the maxillary sinus cavity. *Oral Surg Oral Med Oral Pathol Oral Radiol Endod* 2007;103:623-5.
19. Tabrizi R, Amid R, Taha Özkan B, Khorshidi H, Langner NJ. Effects of exposing dental implant to the maxillary sinus cavity. *J Craniofac Surg* 2012;23:767-9.
20. Khairnar M, Gaur V. Evidence of bone formation in the nasal floor around polished surface bi-cortical screw implants after indirect nasal lift in an atrophied maxilla: Cone beam computed tomography-based case report. *J Indian Soc Periodontol* 2015;19:236-8.
21. Shihab OI. Intentional penetration of dental implants into the maxillary sinus: A retrospective study. *Zanco J Med Sci* 2017;21:1536-9.
22. Elhamruni LM, Marzook HA, Ahmed WM, Abdul-Rahman M. Experimental study on penetration of dental implants into the maxillary sinus at different depths. *Oral Maxillofac Surg* 2016;20:281-7.
23. Kim HY, Yang JY, Chung BY, Kim JC, Yeo IS. Peri-implant bone length changes and survival rates of implants penetrating the sinus membrane at the posterior maxilla in patients with limited vertical bone height. *J Periodontal Implant Sci* 2013;43:58-63.
24. Nooh N. Effect of schneiderian membrane perforation on posterior maxillary implant survival. *J Int Oral Health* 2013;5:28-34.
25. Ghnaem A, Gad HM. The influence of exposing dental implants to the maxillary sinus cavity on sinus complications and implant survival rate: 6 years prospective follow-up. *Egypt Dent J* 2014;60:2-9.
26. Morgano AT. Functional load in oblique bicortical implants: Parasinus implants and palatine implants. *J Oral Implantol* 2013;39:467-74.
27. Lazarov A. Immediate functional loading: Results for the concept of the strategic implant®. *Ann Maxillofac Surg* 2019;9:78-88.
28. Ahmad AG, Osman M, Awadalkreem F. Full-mouth rehabilitation of a patient with cleidocranial dysplasia using immediately loaded basal implant-supported fixed prostheses: A case report. *Int J Surg Case Rep* 2019;65:344-8.
29. Singh M, Batra R, Das D, Verma S, Goel M. A novel approach for restoration of hemisected mandibular first molar with immediately loaded single piece BCS implant: A case report. *J Oral Biol Craniofac Res* 2017;7:141-6.
30. Scortecchi G. *Basal Implantology*. New York: Springer International Publishing; 2019.
31. Ihde S, Kopp S, Maier T. Comparison of implant survival with implants placed in acceptable and compromised bone: A literature review. *J Maxillofac Oral Surg* 2009;8:1-7.
32. Ihde S, Ihde A. *Immediate Loading Guideline to Successful Implantology*. Munich, Germany: International Implant Foundation Publishing; 2010.
33. Ihde S. *Principles of BOI: Clinical, Scientific, and Practical Guidelines to 4-D Dental Implantology*. 1st ed. Berlin, Germany: Springer Science and Business Media; 2005.
34. Ghalaut P, Shekhawat H, Meena B. Full-mouth rehabilitation with immediate loading basal implants: A case report. *Natl J Maxillofac Surg* 2019;10:91-4.
35. Odin G, Misch CE, Binderman I, Scortecchi G. Fixed rehabilitation of severely atrophic jaws using immediately loaded basal disk implants after *in situ* bone activation. *J Oral Implantol* 2012;38:611-6.
36. Ihde S. Restoration of the atrophied mandible using basal osseointegrated implants and fixed prosthetic superstructures. *Implant Dent* 2001;10:41-5.
37. Lazarov A. Trans-and intra-sinus BCS implants: Clinical alternative in advanced maxillary bone atrophy. Statistical analysis of maxillary sinus complications. *Stomatol World* 2018;8. (In Bulgarian).
38. Rosenfeld RM, Andes D, Bhattacharyya N, Cheung D, Eisenberg S, Ganiats TG, *et al.* Clinical practice guideline: Adult sinusitis. *Otolaryngol Head Neck Surg* 2007;137:S1-31.
39. Misch CE, Perel ML, Wang HL, Sammartino G, Galindo-Moreno P, Trisi P, *et al.* Implant success, survival, and failure: The International Congress of Oral Implantologists (ICOI) Pisa Consensus Conference. *Implant Dent* 2008;17:5-15.
40. Albrektsson T, Zarb G, Worthington P, Eriksson AR. The long-term efficacy of currently used dental implants: A review and proposed criteria of success. *Int J Oral Maxillofac Implants* 1986;1:11-25.
41. Mombelli A, van Oosten MA, Schurch E Jr., Land NP. The microbiota associated with successful or failing osseointegrated titanium implants. *Oral Microbiol Immunol* 1987;2:145-51.
42. Loe H, Silness J. Periodontal disease in pregnancy. I. Prevalence and severity. *Acta Odontol Scand* 1963;21:533-51.
43. Statement of the International Implant Foundation IF Concerning Probing Around Basal Implants; 2003. Available from: <http://implantfoundation.org/en/probing-around-basal-implants-2003>. [Last update 2008].
44. Brook I. Sinusitis. *Periodontol* 2000 2009;49:126-39.
45. Bomei SR, Branstetter BF 4th, Ferguson BJ. Frequency of a dental source for acute maxillary sinusitis. *Laryngoscope* 2009;119:580-4.
46. Longhini AB, Branstetter BF, Ferguson BJ. Otolaryngologists' perceptions of odontogenic maxillary sinusitis. *Laryngoscope* 2012;122:1910-4.
47. Lopatin AS, Sysolyatin SP, Sysolyatin PG, Melnikov MN. Chronic maxillary sinusitis of dental origin: Is external surgical approach mandatory? *Laryngoscope* 2002;112:1056-9.
48. Manor Y, Mardinger O, Bietlitum I, Nashef A, Nissan J, Chaushu G. Late signs and symptoms of maxillary sinusitis after sinus augmentation. *Oral Surg Oral Med Oral Pathol Oral Radiol Endod* 2010;110:e1-4.
49. Petruson B. Sinuscopy in patients with titanium implants in the nose and sinuses. *Scand J Plast Reconstr Surg Hand Surg* 2004;38:86-93.
50. Hong YH, Mun SK. A case of massive maxillary sinus bleeding after

- dental implant. *Int J Oral Maxillofac Surg* 2011;40:758-60.
51. Hunter WL 4th, Bradrick JP, Houser SM, Patel JB, Sawady J. Maxillary sinusitis resulting from ostium plugging by dislodged bone graft: Case report. *J Oral Maxillofac Surg* 2009;67:1495-8.
 52. Mombelli A, Buser D, Lang NP. Colonization of osseointegrated titanium implants in edentulous patients. Early results. *Oral Microbiol Immunol* 1988;3:113-20.
 53. Kulak Y, Arikian A, Albak S, Okar I, Kazazoglu E. Scanning electron microscopic examination of different cleaners: Surface contaminant removal from dentures. *J Oral Rehabil* 1997;24:209-15.
 54. Shay K. Denture hygiene: A review and update. *J Contemp Dent Pract* 2000;1:28-41.
 55. Behneke A, Behneke N, d'Hoedt B. A 5-year longitudinal study of the clinical effectiveness of ITI solid-screw implants in the treatment of mandibular edentulism. *Int J Oral Maxillofac Implants* 2002;17:799-810.
 56. Ruedi TP, Buckley RD, Moran CG. *Principles of Fracture Management*. New York: Thieme; 2007.
 57. Prein J. *Manual of Internal Fixation in the Cranio-Facial Skeleton*. Berlin, Germany: Springer; 1998.
 58. Alzarea BK. Assessment and evaluation of quality of life (OHRQoL) of patients with dental implants using the oral health impact profile (OHIP-14): A clinical study. *J Clin Diagn Res* 2016;10:ZC57-60.
 59. Johannsen A, Westergren A, Johannsen G. Dental implants from the patients perspective: Transition from tooth loss, through amputation to implants – Negative and positive trajectories. *J Clin Periodontol* 2012;39:681-7.
 60. Fillion M, Aubazac D, Bessadet M, Allègre M, Nicolas E. The impact of implant treatment on oral health related quality of life in a private dental practice: A prospective cohort study. *Health Qual Life Outcomes* 2013;11:197.
 61. Mukatash GN, Al-Zobe ZR. Implant-supported fixed dentures versus implant-assisted over-dentures: A prospective follow up study of the ability of prosthetic rehabilitation in the mandible to achieve patient satisfaction. *Int J Dent Oral Sci* 2016;3:241-7.